

Dental Scan Ltd.
Suite 17, 75 Harley St, London W1G 8QL

PATIENT: Name Surname
DOB: 12/8/1981
AGE: 39
GENDER: Female
OFFICE: Dr Name Surname
SCAN TYPE: CBCT Upper jaw 10/9/2021
CLINICAL NOTES: UR4 or 5, UL6 for implants.
REPORT TYPE: Pre-implant placement assessment

REPORT DATE: 11/9/2021
STUDY DATE: 10/9/2021
SERIAL #: 6648

OBSERVATIONS**DENTAL FINDINGS:**

Missing teeth: Dentate adult in the focused field of upper jaw UL5 missing.
Implants: No implants are present.
Restorations: The posterior teeth are heavily restored.
Endodontics: Two teeth are endodontically restored and the apical PDL space of both is compromised.
Apical pathology: There is evidence of periapical pathosis on two teeth.
Periodontology: The marginal alveolar bone height is within normal limits.
Third Molars: UR supernumerary tooth distal to UR8 is unerupted, impacted against UR8 with apices touching sinus floor. Possible enlarged follicle space with no erosion of UR8D root and UR8D moderate loss of periodontal bone attachment.

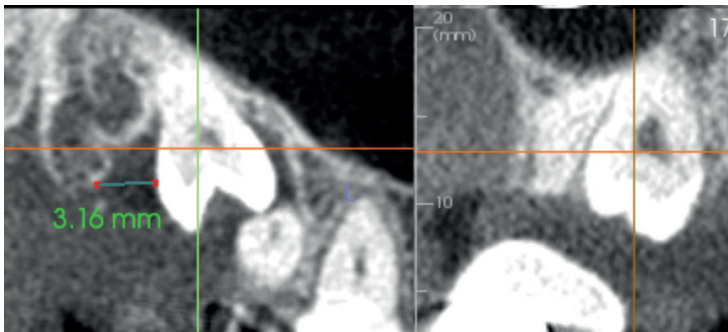
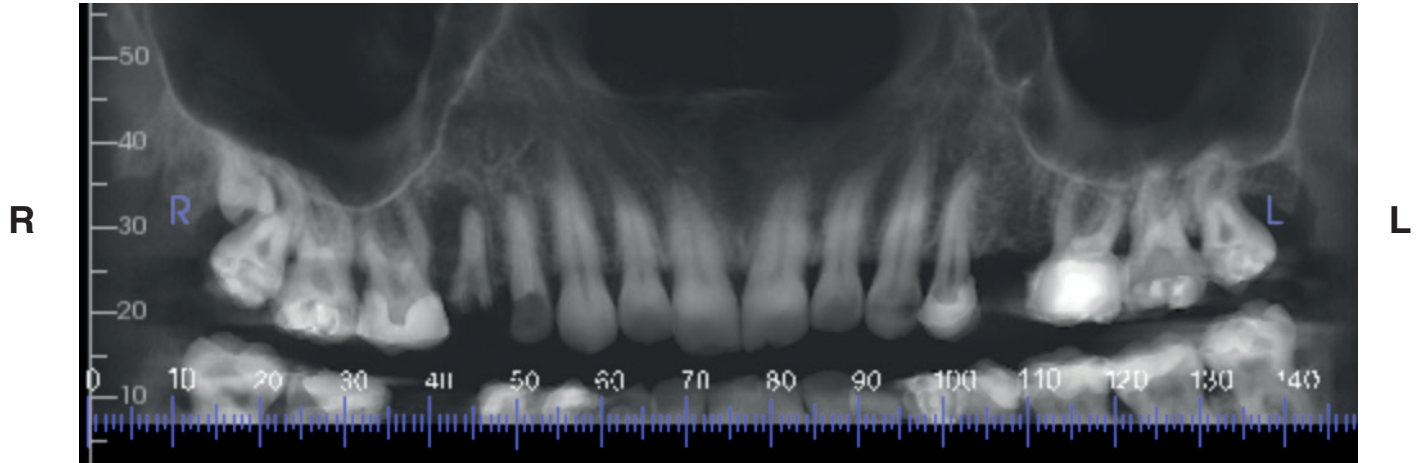
Specific findings: #UR 8-6, UL6,7,8 apices are touching floor of maxillary sinus.
UR5 root treated with a unilocular well defined apical radiolucency 8 x 7 x 6 mm. The epicenter of the radiolucency is midway between UR5-6 with no expansion of the alveolar ridge. UR4 is root treated with an apical radiolucency 1-2 mm wide.
UL5 edentulous region has medium density bone and mild vertical resorption of alveolar ridge.

TMJS: The TMJ articulations are not within the field of view.
SINUSES: The lower portions visible of the maxillary sinuses are clear.
The maxillary sinus ostia regions are not included in the scanned volume.
AIRWAY: The airway is not within the field of view.
CERVICAL SPINE: The cervical spine is outside the field of view.
CALCIFICATIONS: No abnormal calcifications in the field of view.

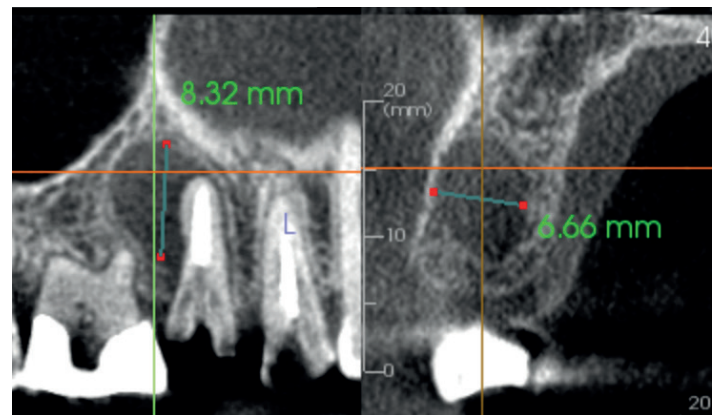
IMPRESSIONS:

Distal to UR8 is an unerupted supernumerary tooth with an enlarged follicle space. This may be a dentigerous cyst. It is suggested that this region is monitored annually for 2 years with periapical radiographs to check for expansion.
UR5 has a large cystic lesion which is probably a radicular cyst. However, the epicenter is not at the apex of UR5 so this could be an Odontogenic Keratocyst, which can recur after removal. It is suggested that you consider the cyst lining is sent for histological evaluation before placing an implant.
UR5 has apical pathology. This is probably an apical granuloma or radicular cyst secondary to chronic apical periodontitis.
UL5 edentulous region has medium density bone and mild vertical resorption of alveolar ridge.

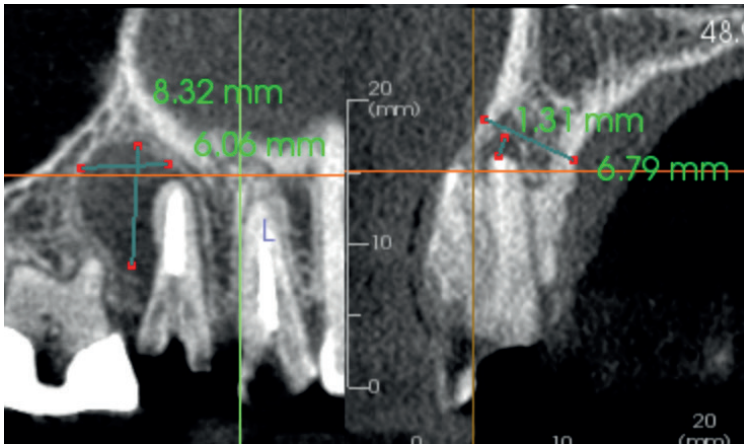
RECONSTRUCTED PANORAMIC IMAGE



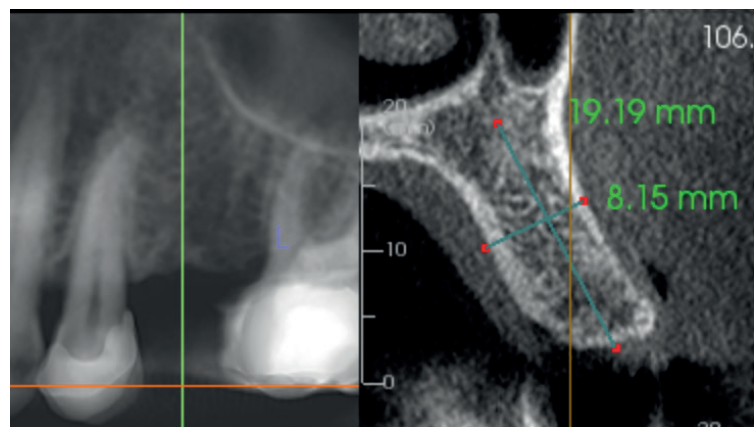
Parasagittal and cross section alveolar ridge: UR supernumerary tooth distal to UR8 is unerupted, impacted against UR8 with apices touching sinus floor. Possible enlarged follicle space with no erosion of UR8D root and UR8D moderate loss of periodontal bone attachment.



Parasagittal and cross section alveolar ridge: UR5 root treated with a unilocular well defined apical radiolucency 8 x 7 x 6 mm. The epicenter of the radiolucency is midway between UR5-6 with no expansion of the alveolar ridge.



Parasagittal and cross section alveolar ridge:UR4 is root treated with an apical radiolucency 1-2 mm wide.



UL5 edentulous region has medium density bone and mild vertical resorption of alveolar ridge.

PLEASE NOTE: Abbreviations used: PLS periodontal ligament space; IANC inferior alveolar nerve canal; CBCT-PAI PeriApical Index. The radiologic findings and impression of this report are developed by Dr. Douglas K Benn, BDS, DDS, PhD, Dip. Dental Radiology (Royal College of Radiologists) Oral and Maxillofacial Radiologist and Professor Emeritus of the University of Florida. The information and/or recommendation(s) contained herein is/are based upon the provided history and imaging rationale, images and volumetric data set and is for consultation purposes only. As with all diagnostic imaging, cone beam CT has diagnostic limitations. Diagnosis, medical advice and treatment is the sole responsibility of the treating physician or dentist.